

SEGMENTATION - DEFINITIONS

ACROSTERNITE - A sternal sclerite derived from a sclerotization of the anterior portion of the primary intermetameric suture.

ACROTERGITE - A tergal sclerite derived from a sclerotization of the anterior portion of the primary intermetameric suture.

ANTECOSTA - The invaginated portion of the sclerotized primary suture following secondary segmentation.

APODEME - A chitinous ingrowth of the exoskeleton to which the muscles are attached.

APOPHYSIS - An elongate projection from the exoskeleton, either internally or externally.

FURCA - In a thoracic segment of higher insects, Y-shaped apodeme formed through the approximation and fusion of the paired sternal apophyses, serving as a site for muscle attachment.

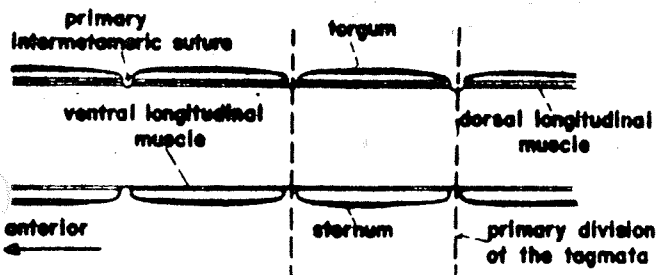
LATEROSTERNITE - The ventral of two sclerites occurring between the tergum and sternum on the longitudinal suture of the abdomen. These are the so-called abdominal pleurites.

LATEROTERGITE - The dorsal of two sclerites occurring on the longitudinal suture of the abdomen. The laterotergite usually embraces the abdominal spiracle.

PHRAGMA - Extensive internal plate developed from an antecostal ridge, providing attachment for the large longitudinal flight muscles of the mesothorax and the metathorax.

PRIMARY SEGMENTATION - the form of segmentation in which the functional intersegmental lines of the body wall coincide with the lines of attachment of the principal longitudinal muscle fibers.

SECONDARY SEGMENTATION - Any form of body segmentation that does not strictly conform with the embryonic metamerism; the usual segmentation of arthropods having a well-developed exoskeleton, in which the membranous intersegmental rings are the posterior parts of the primary segments.



SAGITTAL SECTION OF METAMERES

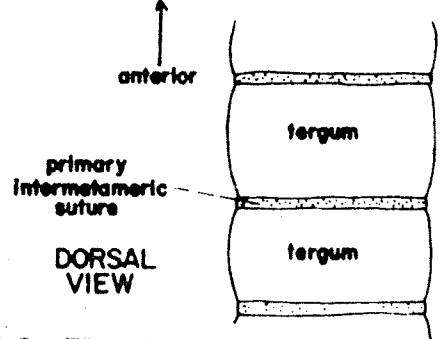


FIG. 7 - PRIMARY SEGMENTATION

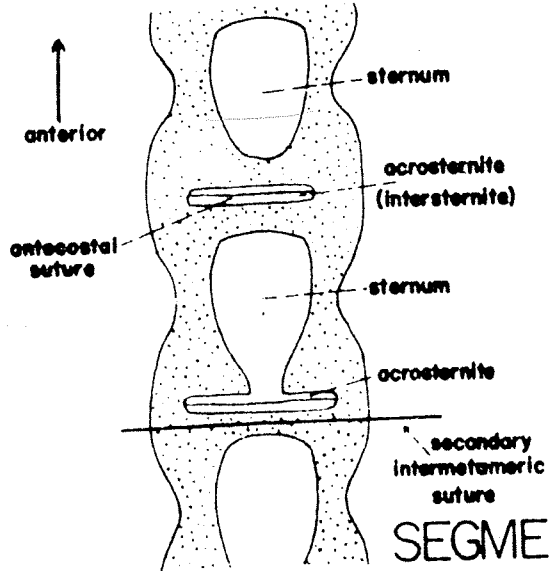
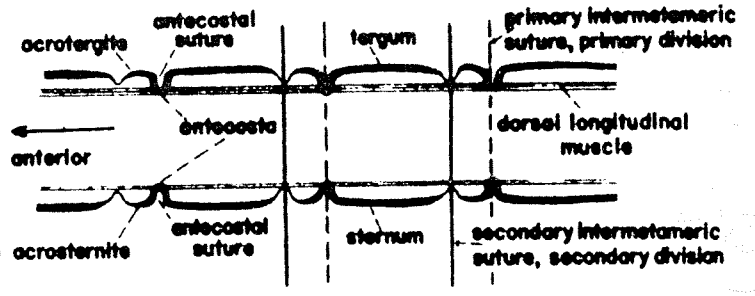


FIG. 9 - SECONDARY SEGMENTATION, THORACIC STERNA



SAGITTAL SECTION OF METAMERES

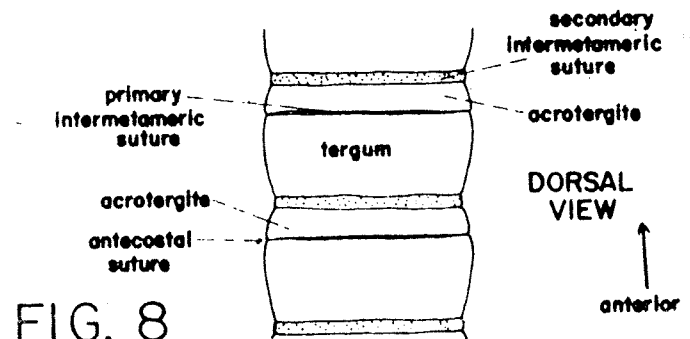


FIG. 8 SECONDARY SEGMENTATION

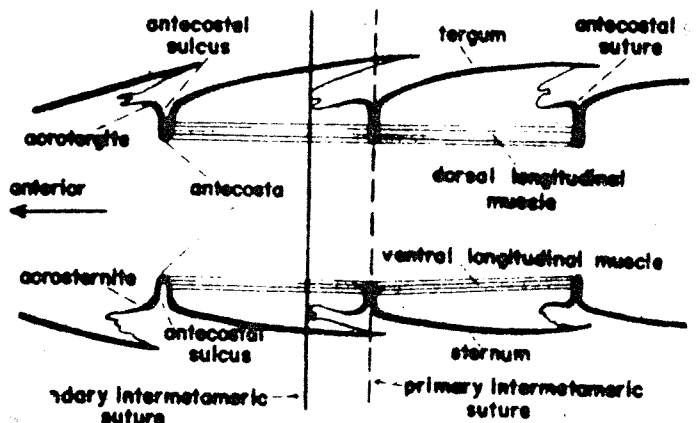


FIG. 10 - THE FUNCTIONAL SECONDARY SEGMENTATION OF THE ABDOMEN

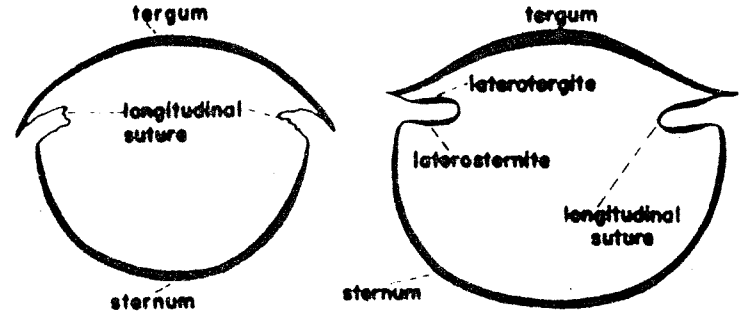


FIG. 11 THE LONGITUDINAL SUTURE OF THE ABDOMEN

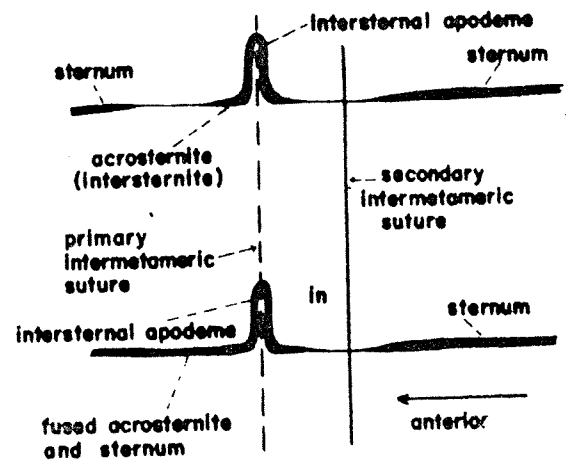


FIG. 9 - SECONDARY SEGMENTATION, THORACIC STERNA